

Restored Brain Perfusion after Non-Invasive Stimulation of the Facial Nerve in a Canine Stroke Model

Andrea García, *Student Member IEEE*, Emilio Sacristán, *Member IEEE*, Joaquín Azpiroz, *Senior Member IEEE*,
Mark K. Borsody

Abstract— Ischemic stroke affects over 15 million patients per year and is a leading cause of death worldwide. Currently available treatments are indicated for less than 5% of patients. Stimulation of the facial nerve has been proposed as a possible new treatment of ischemic stroke that acts by increasing blood flow to the brain and thereby restoring perfusion through collateral vessels. The objective of this project was to evaluate the changes in brain perfusion, following facial nerve stimulation in an animal stroke model using MRI measures of cerebral blood flow. Autologous blood clot was injected in the internal carotid artery to occlude the middle cerebral artery (MCA) in 17 mongrel dogs. Occlusion in the MCA was verified using fluoroscopy and MRI angiography. Following baseline and post-stroke MRI images, the facial nerve at the site of the geniculate ganglion was located and then stimulated using a transcranial magnetic stimulator and a neuro-navigation system in 11 animals. Six animals followed the same procedure but were not stimulated (control group). The perfusion index of both sides of the brain was measured using gadolinium contrast MRI before and after stroke, and at 30 minute intervals after stimulation. Results show a significant and persistent increase in perfusion in the stroke side of the brain relative to the non-stroke / contralateral side, after stimulation, when compared to the control group. These results strongly support the future development and evaluation of a non-invasive facial nerve stimulator device for the early treatment of ischemic stroke.

I. INTRODUCTION

Ischemic stroke is the most common cause of severe disability and a leading cause of death in the United States [1]. Worldwide, there are more than 15 million cases of stroke per year and about 5 million of those are fatal. Emergency treatment of ischemic stroke focuses on restoring cerebral blood flow (CBF) that is blocked by occlusion of a cerebral artery. Since those occlusions are generally caused by a blood clot, emergency treatments for ischemic stroke aim to pharmacologically dissolve blood clots or remove them through endovascular procedures. Tissue plasminogen activator (tPA), which enzymatically breaks down blood clots, is available in many countries

throughout the world for the treatment of ischemic stroke. However, tPA is subject to numerous restrictions that limit its use to less than 5% of all ischemic stroke patients [2,3]. Endovascular procedures employing intra-arterial catheters that physically extract the occlusive blood clot can also be used to treat those cases of stroke caused by occlusion of the large cerebral arteries. Such procedures are appropriate for less than 1% of all stroke patients [4].

Vasodilatory innervations and the effect of direct facial nerve stimulation on CBF is well established in normal animals and its ability to improve CBF in stroke models has also been demonstrated [5-13]. These studies rely on direct electrical stimulation of the facial nerve or its branches, and measure the effect of stimulation using laser Doppler flowmetry or angiography. The objectives of this study was to first demonstrate that facial nerve stimulation can be achieved consistently and effectively using TMS, and then to demonstrate improved perfusion to the ischemic region of the brain in an ischemic stroke model. For this purpose we used magnetic resonance perfusion imaging, which is a well-established technique that has been shown to be effective at detecting and characterizing ischemic tissue [14-17].

II. MATERIALS AND METHODS

A. Surgical Preparation

All experimental procedures were approved by the Ethics Committee of the Universidad Autonoma Metropolitana, CBI. A total of 18 healthy adult mongrel dogs weighing 15-37 Kg were obtained from the animal facility center of the Benemerita Universidad Autónoma de Puebla. Subjects were kept with *ad libitum* access to food and water up until 8 hrs. before the procedures, at which time they were food restricted. All animal were sacrificed after experimentation.

Animals were randomly assigned to one of two groups: stimulation (n=12) or control (n=6) with a 2:1 bias. Anesthesia was induced with intramuscular injection of zoletil (7mg/Kg), propofol (2.5 mg/Kg), and fentanyl (2µg/kg), and anesthesia was maintained with propofol (10mg/kg/hr). Animals were intubated after induction and mechanically ventilated throughout the procedure. Physiologic monitoring included heart rate, blood pressure, oxygen saturation, end-tidal CO₂, and periodic arterial blood gases. All animals were tied down onto a specially designed board so that they could be transferred in and out

*This project was sponsored by Lake biosciences Inc., Orinda CA.

A García, is a graduate student in Biomedical Engineering and E Sacristán and J. Azpiroz are Faculty in the Mexican National Center for Medical Instrumentation and Imaging Research, CI3M, at the Metropolitan Autonomous University, Iztapalapa, Mexico City. (+52 (55) 5970-4869, e-mail: esr@xanum.uam.mx).

Mark K. Borsody MD, PhD, is Chief Medical Officer and founder of Lake Biosciences LLC. Lake Biosciences owns the intellectual property related to non-invasive facial nerve stimulation for the treatment of stroke.

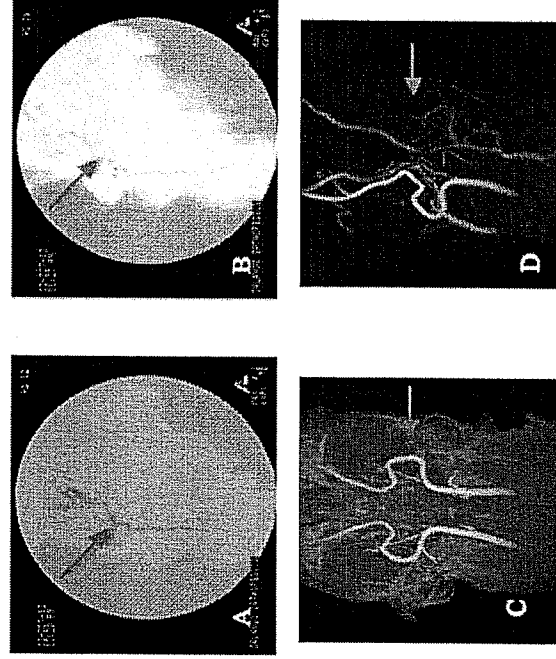


Figure 1. Digital subtraction and MR angiography of a representative animal before stroke (A,C) and after stroke (B,D). The red arrows show the site of occlusion after clot injection.

of the MRI scanner and always be placed in the same position. A series of 6 fiducial markers were glued onto different locations on the head for use as neuro-navigation references. Baseline MRI scans were taken including reference T1 weighted (T1W) and T2 weighted (T2W) images, perfusion, and angiography.

Stroke was induced in all 18 animals by the injection of an autologous blood clot into one of the internal carotid arteries using an intravascular catheter (0.035") introduced via the femoral artery under X-ray angiography. These clots were prepared by taking 20 ml of blood in 1 ml syringes and kept at 4°C for 48 hours before the procedure [13]. Arterial occlusion was confirmed under fluoroscopy with route mapping and digital subtraction by injecting barium sulfate after clot injection to insure blockage of carotid flow to the middle cerebral artery (MCA). Furthermore, loss of CBF (ischemia) was confirmed after MCA occlusion on the second set of perfusion images. One dog allocated to the stimulation group did not exhibit any CBF deficit despite MCA occlusion; this dog was excluded from further analysis.

Following the catheterization procedure, the animals were transferred back to the MRI scanner to repeat the reference, perfusion, and angiography scans.

Animals were then again removed from the scanner. For animals in the stimulation group, we used the T1W and T2W images to locate the geniculate ganglion that then served as the target for facial nerve stimulation. Placement of the TMS coil over the ear on the same side as the

infarction was performed by means of neuro-navigation guidance (Brain Science Tools, Netherlands), and the coil was held in position during stimulation by a locking mechanical arm. Stimulation parameters were determined from previous studies and were fixed for all subjects (no attempt to adjust the threshold to each subject was made) these experiments used a 6.5 cm cooled figure-8 TMS coil (Magventures, Mag Pro, Cool B65). Stimulation consisted of 1.8T biphasic pulses repeated at 10 Hz for 5 minutes.

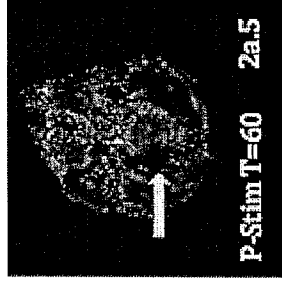
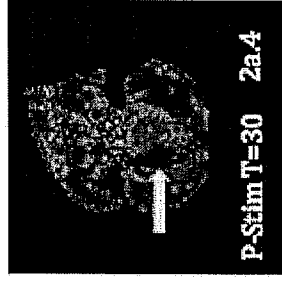
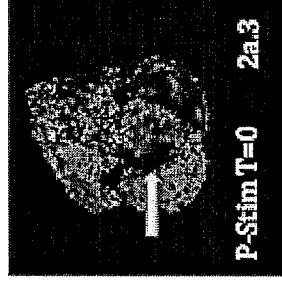
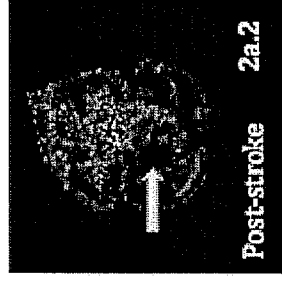

Immediately following stimulation the animals were placed again in the MRI scanner. Perfusion scans were repeated at t=0, 30 and 60 minutes. At the end of each experiment, animals were euthanized by intravenous injection of potassium chloride while under general anesthesia.

B. MRI Data Acquisition and Processing

MRI scans were obtained using a Philips Achieva 3T MRI scanner and an 8 channel SENSE® head coil. T1W and T2W scans of the whole head were obtained as a reference for neuro-navigation using a 3D Fast Gradient Echo sequence. MR angiography was used to confirm arterial blockages using a 3D Phase Contrast Angiography sequence with a FOV of 150mm, centered so that the bifurcation of the carotid could be seen as well as the cerebral arteries and the circle of Willis. For the perfusion and the T2 reference scans we used the same geometry to facilitate registration, with 25 coronal slices spanning the entire brain with a 230 mm FOV. T2 images used a multislice Fast Spin Echo sequence, perfusion used the Philips PRESTO® sequence consisting of 40 dynamic phase contrast images per slice repeated every 1.6s, after a 8 cc bolus of gadolinium based contrast agent (gadopentate dimeglumine 0.5mmol/ml) followed by a 15cc saline flush.

Perfusion index maps were calculated using the PRESTO® Philips software. Twenty- five maps were calculated for each slice at each perfusion scan. For analysis however we focused on only slices number 10 to 14, corresponding to the center of the brain where the ischemia was reliably located. T2W images were used to create a mask and identify and segment brain tissue. We defined two symmetrical square 20 x 20mm ROI, anchored to the same anatomical feature in the center of the brain, for both the stroke side and the non-stroke / contralateral side for each of these five slices. Then, we calculated the average perfusion index at each time point. To eliminate variations from scan to scan and from subject to subject we normalized the perfusion index on the stroke side to that of the non-stroke / contralateral side. Average normalized perfusion index at baseline, post-stroke, and at T=0, T=30, T=60 post-stimulation of the stimulation group were compared to the control group using a one-sided Welch t-test at each post-stimulation time point.

Stimulation Group



Control Group

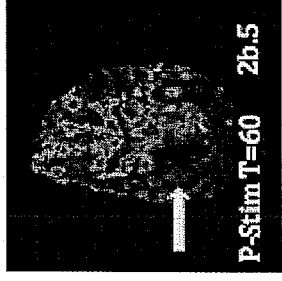


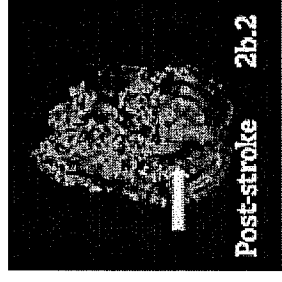
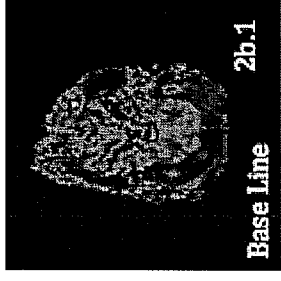
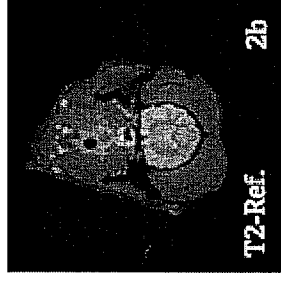


Figure 2. Perfusion index maps of a stimulated animal (left) and a control animal (right). T2 Ref is a T2 weighted reference image used to localize the brain. "Baseline" are images before inducing stroke, "Post-Stroke" are images after occlusion, and "P-Stim" are images at T=0 min, 30 min, and 60 min after stimulation of the facial nerve on the same side as the stroke. The arrows show the localization of the ischemic brain region.

III. RESULTS

The region of brain ischemia was evaluated with perfusion MRI. Figure 2 shows examples of perfusion index measures for each group: baseline (Fig 2a.1 & 2b.12) for a control and stroke subject, post stroke (Fig. 2a.11 & 2b.2), and the time line of post-stimulation measures. Figure 3 shows the group averaged effect on perfusion index of facial nerve stimulation. Overall, the average perfusion of the ROI on the stroke side was decreased by 70% after occlusion, and it stayed at those depressed levels for the control group- whereas was returned toward normal by facial nerve stimulation. The effect of the 5-minute period of facial nerve stimulation was found to be durable for at least 60 minutes post-stimulation.

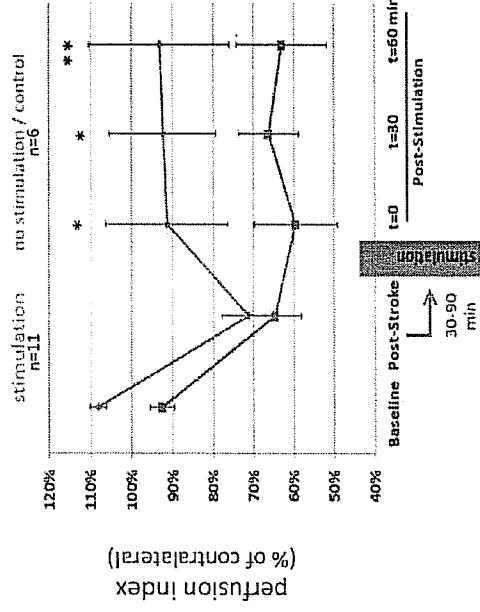


Figure 3. This graph shows the mean perfusions index of the stroke side of the brain relative to the normal side. 11 stimulated dogs are included and 6 control dogs. Error bars are std. error of the means. The blue arrow marks the time point of stimulation.
*, $p=0.05$ ***, $p=0.10$

IV. DISCUSSION

We used the dog model of stroke because it closely resembles the clinical condition of human embolic stroke. In this model, autologous blood clot was injected into the distal internal carotid artery and allowed to lodge in the MCA, but we could not precisely control the site of occlusion. As a result, the size and location of the infarct was variable among subjects. Indeed, one dog did not demonstrate any area of CBF loss after MCA occlusion, and had to be excluded from stimulation. This again resembles clinical reality. Despite this variation in infarct location and size, the effect of magnetic stimulation of the facial nerve was evident and statistically significant.

This model may have also caused an unintentional bias in our results: we found that the right side of the brain in all baseline measures had about 5% higher perfusion than the left. The necessity of allowing the interventionalist to choose the side of blood clot injection unintentionally resulted in more right-sided stroke experiments in the stimulation group, whereas controls had stroke more often on the left side. (This effect can be seen in the baseline measures of Figure 3.) However, even after subtracting this difference from the right-sided stroke subjects, the difference in average perfusion after stimulation was still significant.

For this study, we used the baseline reference MRI images and a neuronavigation system to place and focus the stimulation coil in every single case in the stimulation group. Proper stimulation of the facial nerve was evident by simultaneous twitching of face muscles, eyelids and shoulder. Small deviations in coil placement (in the order of 1 cm) could cause the effect of the facial nerve stimulation to disappear.

V. CONCLUSIONS

Results show a significant and persistent increase in CBF to the ischemic brain following TMS stimulation of the facial nerve. The non-invasive nature of the stimulation, the fact that the effect seems to persist long after stimulation, and the fact that the observed increase is quite large, all suggest that this method could have clinical benefit in the treatment of stroke patients. Although several technical challenges can be foreseen, these results strongly support the future development and evaluation of a specific device for the early treatment of stroke based on magnetic stimulation of the facial nerve.

ACKNOWLEDGMENTS

The authors would like to thank Fernando Castro, MD, responsible for the endovascular procedures of the stroke model. Gerardo Villanueva MD, and Ramon Torres, DVM, in charge of anesthesia and animal care, Ivan Mejia, Rad. Tech, responsible for the operation of the MRI and Angiography systems, and finally to the members of the C3M team: Rafael Lara, Fernanda Maldonado, Lucia Trejo and Andres Morón for their general help with these experiments.

REFERENCES

- [1] Lloyd-Jones D, Adams RJ, Brown TM, et al. "Heart disease and stroke statistics – 2010 update: A report from the American Heart Association." 2010. *Circulation* 121: e46-215.
- [2] Barber PA, Zhang J, Demchuk AM, Hill MD, Buchan AM. "Why are stroke patients excluded from tPA therapy? An analysis of patient eligibility." 2001. *Neurology* 56: 1015-20.
- [3] Cloft HJ, Tomsick TA, Kallmes DF, Goldstein JH, Connors JJ. "Assessment of the interventional neuroradiology workforce in the United States: A review of the existing data." 2002. *AJNR* 23: 1700-5.
- [4] Borsody, MK, "Modulating function of the facial nerve system or related neural structures via the ear", U.S. Patent Application 2011/0270361 A1, Nov. 3, 2011.
- [5] D'Alecy LG, Ross CJ. "Parasympathetic cholinergic control of cerebral blood flow in dogs." 1977. *Circ Res* 41: 324-31.
- [6] Forbes HS, Schmidt CF, Nason GI. "Evidence of vasodilator innervations in the parietal cortex of the cat." 1939. *Am J Physiol* 125: 216-19.
- [7] Goadsby PJ. "Effect of stimulation of facial nerve on regional cerebral blood flow and glucose utilization in cats." 1989. *Am J Physiol* 257: R517-21.
- [8] Goadsby PJ. "Sphenopalatine ganglion stimulation increases regional cerebral blood flow independent of glucose utilization in the cat." 1990. *Brain Res* 506: 145-8.
- [9] Goadsby PJ. "Characteristics of facial nerve--elicited cerebral vasodilatation determined using laser Doppler flowmetry." 1991. *Am J Physiol* 260: R255-62.
- [10] Goadsby PJ, Hoskin KL. "Cerebral blood flow is not coupled to neuronal activity during stimulation of the facial nerve vasodilator system." 1994. *Brain Res* 647: 192-8.
- [11] Linder J. 1981. "Effects of facial nerve section and stimulation on cerebral and ocular blood flow in hemorrhagic hypotension." *Acta Physiol Scand* 112: 1857-93.
- [12] Salanga VD, Waltz AG. 1973. "Regional cerebral blood flow during stimulation of seventh cranial nerve." *Stroke* 4: 213-17.
- [13] Shatbani A, Khawar S, et al. "First results in an MR imaging-compatible canine model of acute stroke." 2009. *AJNR* 27: 1788-1793.
- [14] Schaefer Pamela W, Orsinar Yelda, et al. 2003. "Assessing Tissue Viability with MR Diffusion and perfusion Imaging." *AJNR* 24:436-443.
- [15] Srinivasan Ashok, Goyal Mayan et al. 2006. "State of the art imaging of acute stroke." *RadioGraphics*: 26:S75-S95.
- [16] Van der Born I.M.J., Mehra M, et al. 2012. "Quantitative evaluation of C-Arm CT cerebral blood volume in a canine model of ischemic stroke." *AJRN*: 33: 353-58.
- [17] Bristow M S, Simon J E, et al "MR perfusion and diffusion in acute ischemic stroke: human gray and white matter have different thresholds for infarction." 2005. *J Cereb Blood Flow Metab* 25: 1280-7.